

Ringworm

Ringworm in an individual animal is a nuisance; however, ringworm in an animal shelter can lead to completely unmanageable outbreaks, thousands of dollars in diagnostic and medical costs, the possibility of spread to adopters and staff, and an intolerable blow to the shelter's status in the community. It is vital to have a consistent and effective strategy to prevent and manage this disease.



Woods lamp positive

This guidebook is part of a resource library maintained jointly by the Shelter Medicine Programs at the University of Wisconsin and UC Davis. The latest version of this document and all other shared resources can be found at their respective websites.

This content is licensed under a [Attribution-NonCommercial-NoDerivatives 4.0 International](#)

Last updated on Apr 12, 2018

Ringworm (Dermatophytosis)

What is Ringworm?

Ringworm, or "dermatophytosis", is a fungal infection affecting the skin, hair and occasionally nails of animals (and people). Three species of ringworm fungus most commonly affect cats and dogs:

- [Microsporum canis](#)
- [Microsporum gypseum](#)
- [Trichophyton mentagrophytes](#)

Who gets Ringworm?

The dermatophyte species that affect cats and dogs can be passed between these two species as well as to humans and other mammals. Factors that increase risk of ringworm:

- **Age** - Animals of any age are susceptible, but young animals (<1 yr old) and geriatric animals are at the highest risk.
- **Species and breed** - Cats are at greater risk than dogs. Persian cats and Yorkshire Terriers are at relatively high risk, as are long-haired cats in general.
- **Immune status** - Animals with conditions that compromise the immune system such as FIV, FeLV, pregnancy/lactation, malnutrition, anti-inflammatory drugs, cancer, or stress are at an increased risk.
- **Preexisting Conditions** - Animals with pre-existing conditions that compromise grooming (e.g. URI) or skin integrity (e.g. flea allergies, over-grooming, external parasites) are at increased risk.

How is Ringworm Spread?

M. canis is most often spread from contact with an infected animal or a contaminated environment, and therefore is by far the most likely to be a serious problem in a shelter. *T. mentagrophytes* is thought to be contracted mainly from exposure to rodent nests, and *M. gypseum* from contaminated soil, though the potential exists for spread from animal to animal in a contaminated environment.

Ringworm is very durable in the environment. Ringworm can persist on any surface and can infect animals housed in a contaminated environment months and even years later. *For more information, refer to [Environmental Decontamination](#) in this guidebook.*

Ringworm can be spread readily on grooming implements, contaminated toys and bedding, or by humans on clothing and hands. In nature, the incubation period for ringworm is between 4 days and 4 weeks. Ringworm can be found on the hair of animals from a contaminated environment even when the animal itself is not showing any signs.

Diagnosing Ringworm

Accurate diagnosis of ringworm is very important: the consequences of a false positive test may be severe for the individual animal diagnosed, especially at agencies that must euthanize ringworm positive animals. The consequences of a false negative may be even more severe, as it may allow an infected individual to spread ringworm within a facility or to a foster or adoptive home. Unfortunately, there is no rapid, reliable test for diagnosis of ringworm. There are ways to confirm its presence, but no definitive way to confirm absence except by careful fungal culture and microscopic examination.

If it is necessary due to practical considerations to make a “best guess” without

performing a fungal culture, then history, clinical signs, and results of a Wood's lamp examination should be considered together. For instance, a classic ring shaped lesion in a kitten, especially if multiple members of a litter are affected, is very likely to be ringworm even if Wood's lamp results are negative. On the other hand, ringworm is uncommon in adult dogs, so even a suspicious lesion is more likely to have another cause unless there is a highly suggestive history (i.e. known recent exposure, endemic area).

Recently (March 2015) [IDEXX Laboratories introduced the Ringworm RealPCR™](#) for diagnosing ringworm. From our experiences all suspect animals should still have cultures run to confirm the presence or absence of the fungus.

Clinical appearance

The name "ringworm" comes from the most common appearance of a circular area of hair loss and scaling. The most common locations include the face, ears, feet and tail. However, ringworm can present with a wide range of appearances, including large areas of hair loss with or without crusts and exudate. Ringworm can also cause infection of the toenails and nail beds. Ringworm lesions may or may not be pruritic (itchy).

There are other possible causes for all the types of lesions described above, so definitive diagnosis based on appearance alone is not possible. Not all areas of alopecia are due to ringworm. There typically is also evidence of inflammation - redness of the skin, swelling, warm to the touch, and itchy or painful. In a shelter study, the majority of cats with skin lesions were not infected with ringworm, AND a significant number of cats with no grossly apparent lesions were culture positive. Therefore, fungal culture should ideally be used to confirm or rule out ringworm in all cats, especially those at high risk due to presence of skin disease, breed or exposure risk. *For more information, refer to Who gets Ringworm?* in Chapter 1. The most common differential diagnoses for hair loss to be considered include demodectic mange and staphylococcal folliculitis.

Wood's lamp

A [Wood's lamp](#) is an ultraviolet light with a specific wave length of light which causes some strains of *Microsporum canis* to fluoresce. Although not a perfect diagnostic test due to the relatively high frequency of false negative results, a Wood's lamp - correctly used - can be a helpful and cost effective screening tool. It has been estimated that somewhere between 30-80% of *M. canis* strains will fluoresce; the actual frequency in ringworm-infected cats has not been documented but may be higher than the 50% commonly quoted. Bright apple green fluorescence coating the hair shafts is strongly suggestive of infection and warrants isolation and fungal culture. A negative Wood's lamp exam does not rule out infection and suspicious lesions should always be cultured. Some drugs and other products, notably tetracycline drugs and ointments (e.g. doxycycline, terramycin), will also fluoresce. Fluorescence induced by dermatophyte infection can be distinguished from fluorescence due to contaminants by the fact that ringworm can not be easily rinsed off. Observation of known lesions will help develop proficiency in recognizing true fluorescence. In order to maximize the usefulness of this test, it is important to use the right equipment, correctly:

- A true Wood's lamp should be used, as opposed to a generic UV light.

Woods lamps fluoresce at a particular wave length (360 nm).

- A plug-in, rather than battery model, is ideal as the stronger light is more likely to generate fluorescence.
- Perform the exam in a completely dark room, and allow your eyes to adjust before performing the exam
- Hold the lamp no more than 4-10 cm away from the animal.
- **Look the animal over carefully, especially on the face, feet, belly, and inside the ears.**
- **[Here](#) is an excellent video of how to do a thorough Wood's lamp exam.**

Although absence of Woods lamp fluorescence by no means rules out ringworm infection, a positive result is a good indicator to at least isolate the animal until fungal culture results can be determined.

Direct Microscopic Examination (Trichogram)

Positive Wood's lamp findings and direct microscopic examination can diagnose ringworm, but negative findings do not rule it out. Direct microscopic examination is used to confirm the results of Wood's lamp tests and may be especially useful if the Wood's lamp test is equivocal. Results can be improved through practice.

Hair may be suspended in mineral oil and examined directly. Some people recommend clearing the sample of keratin by suspending it in 10-20% KOH or chlorphenolac prior to examination but we have not found this step to be necessary and these substances are corrosive to microscope lenses.

Infected hairs appear swollen, frayed, irregular or fuzzy in outline, and the normal structure of cuticle, cortex, and medulla is lost. Arthroconidia (beaded chains of small rounded cells) and hyphae can sometimes be seen. Hyphae are uniform in diameter, septate and variable in length and degree of branching. Dermatophytes do not form macroconidia in tissue, so any macroconidia seen represent other species of fungus.

Recognition of affected hairs takes practice. To get experience in making a diagnosis by this method, examine known infected hairs from a Woods lamp-positive lesion. Doubtful cases should be cultured.

Fungal culture

Ultimately the only truly reliable way to diagnose ringworm is via fungal culture. Performance of this test in-house where possible, as opposed to sending it out to a diagnostic laboratory, has several advantages. In order to properly manage an outbreak of ringworm affecting multiple cats, numerous cultures are required: for risk assessment in exposed cats, diagnosis of suspect lesions and confirmation of cure after treatment. This can quickly become a prohibitive expense if cultures are not done in a cost effective way. Reading cultures in-house also permits a speedier diagnosis in positive cases – growth often occurs within a week, allowing earlier initiation of treatment. The amount of growth on a culture plate can help differentiate possible carriers from truly infected cats. Foster parents can be instructed in the proper technique for toothbrush culture collection, and can simply bring samples in for ongoing monitoring purposes rather than bringing in all the infected cats each time.

Notes on Successful Ringworm Culture


Plate-style cultures are easier to inoculate via toothbrush than narrow jars or slants. They are also easier to collect samples from for microscopic examination. Plates that combine dermatophyte test medium on one side to give a red color change with most species of dermatophytes with rapid sporulating medium or Sabouraud's dextrose agar to aid in microscopic identification of colonies on the other side, are ideal. Plates can be ordered from [Hardy Diagnostics](#).

For single lesions:

- Pluck plenty of individual hairs using hemostats or a gloved hand from suspect lesions (if hairs are Wood's lamp positive, choose those).
- Press hairs firmly onto culture.
- Even for those animals with lesions, toothbrush culture may be preferred as described below.

For animals with no lesions or multifocal lesions (toothbrush culture):

- If coat contamination is suspected, wipe the animal down with a damp cloth prior to culture.
- Using a toothbrush from a freshly opened package, brush the animal at least 30 times being sure to include around the face, inside and outside of pinnae, and around the nail beds. Do the suspicious areas last.
- If toothbrushes are transported prior to culture inoculation, make sure they are not exposed to high heat (e.g. in a hot car) as this can destroy spores and lead to false negative culture results.
- Make sure culture medium is at room temperature when inoculated.
- Press the toothbrush firmly into culture medium, but not so firmly that the culture medium is disrupted.
- **Don't forget to label the sample with date and animal ID number.**
- Maintain the culture at 80-86 °F. *If the shelter does not have a handy incubator, refer to [How to Make a Homemade Incubator](#).*
- Examine the cultures daily to monitor growth. The great majority of cases of *M. canis* in untreated animals will grow within 10 days, but plates should be held for 21 days just in case (*Trichophyton* species can take longer to grow). Although culture kits are available that claim to give results in less than 10 days, these are not reliable.
- Always confirm species microscopically - some non-pathogenic fungi can look a lot like ringworm to the naked eye. Ringworm species will develop colony growth at the same time as color change develops in the medium. In addition, ringworm species have a characteristic white, fluffy colony appearance, whereas other fungal species will often appear yellow, green, or slimy.



M. canis growth (as identified on microscopic exam) on a DTM Plate

Identification

Not all dermatophytes turn the dermatophyte test medium red, so false negatives are possible. Some other types of non-pathogenic fungi can cause the red color, so false positives are possible too. To be certain of a diagnosis of ringworm, it is imperative to microscopically examine and positively identify the fungus. The culture on rapid sporulating medium can be microscopically examined as well to positively identify the fungus present.

This is accomplished by microscopic examination of a “tape prep”:

1. Place a drop of lactophenol blue stain on a slide.
2. Dab the sticky side of a piece of tape on the suspect colony.
3. Place the tape over the drop of stain and examine under the microscope.

Most culture media kits come with a guide to microscopic identification. Descriptions and photos for fungal identification can be found in [Muller and Kirk's Small Animal Dermatology](#), 7th Edition (Saunders), chapter 2, Diagnostic Methods.

Responding to Positive Cultures

No matter what species of ringworm you identified on the culture plate, your first step after identifying the species is to count the number of colonies growing on the plate. This is called a pathogen-score or “p-score.”

- P1: 1-4 colonies identified
- P2: 5-9 colonies
- P3: > 10 colonies

The number of colonies growing can be an indication of whether the cat is truly infected or not.

A positive culture means that spores were present on the fur when you cultured the cat, but it is possible the cat is not truly infected. Cats with a low p-score and no visual lesions are called “dust mops,” and they are not a high risk for becoming infected or infecting other animals/people.

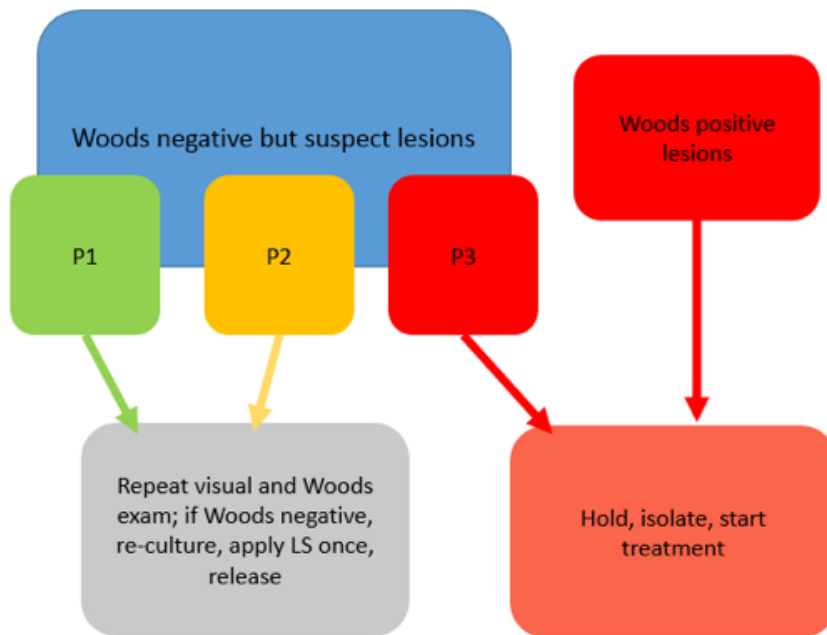
A P3 culture generally indicates a true infection. P1 or P2 may mean a true

infection or may mean the cat was a “dust mop.”

After assigning a p-score to the culture plate, the next step is to repeat your visual exam to look for suspicious lesions on the suspect cat. If you identified *M. canis* on the culture plate, you should also repeat a Wood’s exam.

- If skin lesions are present *or* you have a P3 culture, begin topical and oral treatment for ringworm.
- If skin lesions are not present and you have a P2/P1 culture, thoroughly examine the cat again. If no lesions are noted, re-culture the cat, “dip” the cat once and move along through the system.

Response plan for suspect animals with positive cultures for *M. canis*



How to Make a Homemade Incubator

Use any clean plain plastic bin with a lid.

Place on top of a low-heat heating pad wrapped in a towel (the ones without timed auto-shutoff are ideal, such as the ones that come with some dog beds). Place a fish tank thermometer and a damp paper towel in the bin and monitor a 2-3 times per day before using it for cultures to determine what the temperature range in the bin is. The ideal temperature range is 80-86 °F (27-30 °C).

If the temperature is too warm trying placing additional layers between the bin and the heating pad. If the temperature is too cool reduce the layers or try wrapping the entire bin in layers to help hold in the heat.



Treating Ringworm

In most cases, pet animals spontaneously recover from ringworm within about 3 months. Awaiting self-cure is certainly a reasonable choice in a single animal household with no young children or immunocompromised adults where contagion is not a major concern. However, in a shelter environment or foster situation, a more rapid resolution is highly desirable. Reducing environmental contamination is just as important as treatment directed towards speeding recovery of affected animals.

Topical Treatments

The most important component of treatment in a population is topical therapy.

This is critical in order to reduce immediate and ongoing environmental contamination. This is best accomplished through the use of topical therapy which sterilizes the coat and prevents the further growth of spores that can re-contaminate the environment.

Of all available topical therapies, lime sulfur solution is the most effective as it sterilizes the coat to prevent further growth of ringworm, is relatively easy to apply rapidly to a number of cats, and has been documented to work well in a shelter setting.

Laura Mullen, CAWA, founder of the San Francisco SPCA's SPORE program, presents "Tips to Dip: How to Dip Cats and Kittens for Ringworm Using Minimal Stress Handling" (above).

Miconazole shampoo in combination with chlorhexidine may also be effective; chlorhexidine alone is not. Enilconazole solution, although reportedly effective, is not available for this use in the United States (it is regulated by the EPA rather than the FDA, which does not permit off-label use in the same way). Some currently available topical treatments are ineffective or only partially effective; use caution if selecting another treatment other than lime sulfur solution.

Chlorhexidine shampoos and locally applied topical ointments do not effectively sterilize the coat or provide residual activity against further

growth. Topical terbinafine (Lamisil) and clotrimazole (Lotrimin), are not recommended for use in pets as they do not reduce further growth of ringworm lesions.

Pure Oxygen® Shampoo (accelerated hydrogen peroxide shampoo by Ogena Solutions) may eliminate ringworm spores from the coat. More studies are needed to determine the efficacy of Pure Oxygen® Shampoo as a topical treatment for ringworm.

Lime Sulfur Use

- Use 8 ounces per gallon of warm water (note: this is twice the recommended concentration listed on the bottle).
- Apply twice weekly throughout treatment.
- Safe to use on pregnant and nursing animals and kittens/puppies > 2-3 weeks old.
- Wipe nursing moms' teats clean after topical treatment, keep juveniles warm with a heating lamp or warming blocks if necessary.
- E-collar afterward is not necessary.
- [Do not pre-wet the animal.](#)
- Consider using a **new** garden sprayer for application. Be sure to keep sprayer end close to the animal's skin when applying.
- Use a small rag or sponge to apply solution on face, nose and ears.
- Use of ophthalmic lubrication ointment to protect the cat's eyes is not recommended because if the solution gets into the eye it can be very difficult to remove the solution if it is mixed with lubricant. Instead, keep eye flush handy and flush generously if solution gets into cat's eye.
- Do not rinse the animal after solution application; wrap the animal in a towel and leave to dry.

Please note: physically dipping cats in the lime sulfur solution is not recommended as this is stressful to the cats (and staff) and can lead to cross contamination between cats being treated if the same lime sulfur dip solution is used on multiple cats.

Systemic treatment

Systemic treatment is an important adjunct to topical therapy, especially in a shelter where time-to-cure is an important consideration. Extended stays in a shelter or foster care increase the chance of spread, use precious isolation space, and may reduce the adoptability of the patient, especially if kittens are allowed to grow old in treatment.

The drawbacks of systemic treatment are the relatively high cost of the drugs and the possibility of toxic side effects. Itraconazole is a good choice due to its demonstrated efficacy, relative safety, and long half-life in the skin. We do not recommend compounded itraconazole as it has repeatedly been shown to be less effective and may result in treatment failure.

Fluconazole and terbinafine are also reportedly effective. Griseofulvin is effective, but more likely than itraconazole to cause toxic side effects. Ketoconazole should be avoided in cats if possible, as it can cause hepatotoxicity in this species. Lufenuron (Program) has been shown in repeated studies to be **ineffective**.

Animals on any systemic antifungal should be closely monitored, and all directions for administering the drugs carefully followed. These drugs should be avoided in pregnant animals.

Clipping and Shaving

Clipping is often unnecessary in short and medium haired cats, and may worsen lesions through micro-trauma and mechanical spread of spores. However, clipping is indicated for very long haired cats and those that may be unable to groom due to conformation (e.g. Persians), concurrent severe upper respiratory congestion, or matted coat. Clipping may also be useful in cats whose coats simply become unmanageable after dipping.

Clipping should be performed gently with a #10 blade, taking great care to avoid clipper burn, and hair should be carefully disposed of. Clipping with a closer blade causes excessive trauma and increases the chance of worsening lesions. Clipping should be performed in a room that is easily cleaned since it causes heavy environmental contamination, and instruments used should be carefully cleaned and dedicated only to that purpose, never used on healthy animals (i.e. do not use the surgery clippers for ringworm cats!).

It is important to wear protective clothing whenever handling a ringworm animal in a shelter, and especially when clipping. In a facility with an easily cleaned/disinfected euthanasia room, this might be a good place for clipping ringworm cats.

Treatments That Do NOT Work

Although many treatments are reportedly effective for individual animals, the frequency of self-cure makes these claims somewhat difficult to assess in the absence of supporting scientific evidence. In a population setting, treatment failure is more evident and common, and the requirements for highly effective treatment are rigorous. The following treatments have failed to demonstrate efficacy in controlled studies:

- Lufenuron (Program)
- Topical creams and ointments
- Chlorhexidine as a shampoo or disinfectant
- Potassium peroxymonosulfate (Trifectant) as a dip

“Natural” treatments often suggested on well-meaning pet websites such as apple cider vinegar, coconut oil, tea tree oil, papaya, garlic, grapefruit seed extract, colloidal silver, betadine, and topical bleach are not effective and some of these home remedies are toxic to pets.

Pulse therapy is complicated and difficult to keep track of in a shelter setting. It requires a loading dose and ultimately does not reduce the amount of drug used in treatment. Therefore, pulse therapy is not recommended.

Verifying Cure

It is imperative to recognize that animals can still carry infective fungi even after signs appear to have completely resolved. Animals may be considered cured after 3 consecutive weekly fungal cultures are negative. (If twice weekly lime sulfur and systemic itraconazole are used, 2 cultures may be adequate).

Fungal culture should be obtained, using the toothbrush collection method, starting at week 1 of treatment. Animals housed in a contaminated environment may become incidentally contaminated. If this is a concern, the animal should be kept in a clean cage or room for 5-10 days prior to obtaining the culture.

Because the fungal cultures take about two weeks to verify negative results, this means that treatment and documentation of cure will take a minimum of 6-8 weeks, and may take as long as 3-4 months. Housing and socialization of the animal during this period are extremely important considerations when deciding whether treatment in the shelter is practical.

Preventing Ringworm in a Shelter Setting

There is currently no vaccine available that is protective against ringworm.

The best protection, as with many infectious conditions, is to practice excellent husbandry. All cats should be screened with a Wood's lamp receive a careful visual examination at intake and prior to being placed in foster homes.

Remember that some cases will not be detected with the Wood's lamp. For areas with high levels of ringworm, all kittens or litters should be housed separately in an easy to disinfect area for at least two weeks and observed before being allowed the run of a house (recalling that the incubation period is 4 days to 4 weeks, so this quarantine will catch some but not all cases).

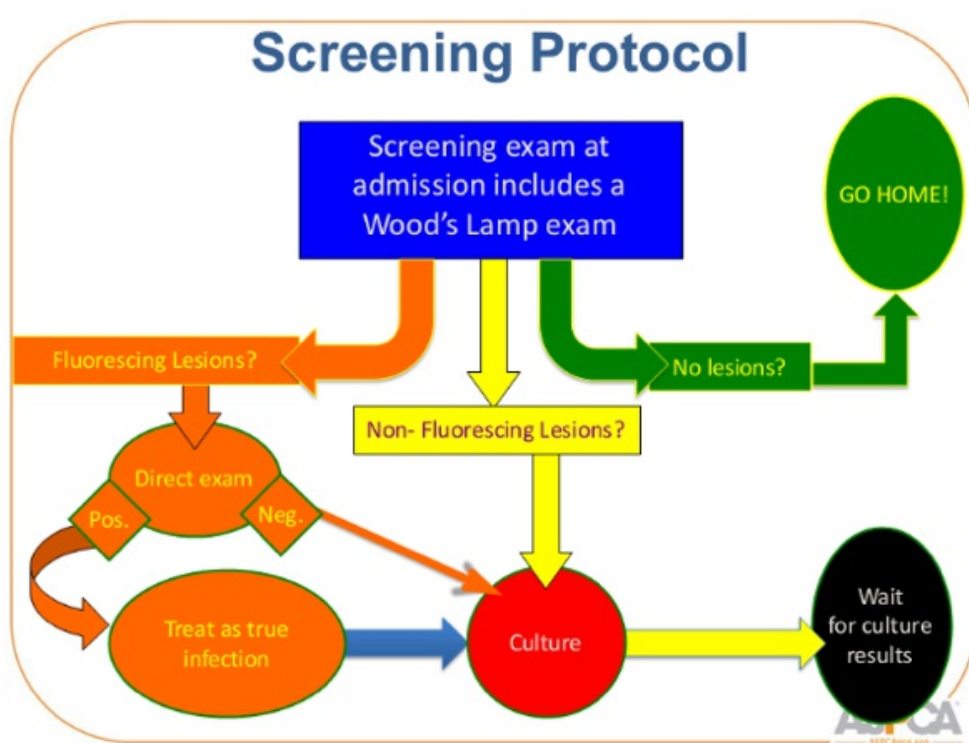
Identify Affected Animals

1. Carefully inspect all incoming animals and all animals being considered for foster care or group housing. Look for any areas of hair loss, scabbing, or crusting, especially focal areas affecting the face, ears, feet or tail.
2. Perform Wood's lamp examination of all cats on intake as well as anyone with suspicious lesions. Use correct technique and recognize the limitations of this exam (false negatives are uncommon, but possible).
3. Direct microscopic examination (trichogram) of hairs from suspicious lesions. Practice technique and recognize limitations (false negatives possible).
4. Fungal culture and microscopic identification in all cases where definitive diagnosis is required.

Visual Exam	Wood's Exam	Ringworm infection?
No Lesions on Skin or Fur	Negative	No
No Lesions on Skin or Fur	Positive	Suspect. Perform Trichogram. If trichogram positive, cat has ringworm infection; if negative, hold for culture.

		Dip, isolate, and clean last.
Lesions on Skin or Fur Present	Negative	Suspect. Hold for culture. Dip, isolate, and clean last.
Lesions on Skin or Fur Present	Positive	Yes

Ringworm 101 for Shelters Webinar



Segregate Affected Animals From the General Population

Isolate affected or suspected animals and institute cleaning protocols to prevent further spreading. **It is not necessary to completely isolate suspect or infected animals in a separate building as long as appropriate environmental cleaning is initiated.**

- All surfaces with which ringworm suspect animals have had contact should be immediately cleaned, then disinfected. This includes floors, carriers, transport vehicles and countertops.
- Clearly identify suspect animals (i.e. post a sign on their cage).
- Housing affected and suspected animals individually in cages that can be

easily cleaned will allow easier identification of cure but in many cases the benefits of socialization warrant co-housing of kittens or bonded pairs during the treatment period. Large litters should be split into multiple housing cohorts (2-3 per cage) after weaning.

- In foster care, house in large dog crate or easily cleaned room such as bathroom until at least two weeks of effective topical treatment has been completed.
- Ideally, house ringworm suspects separately from other animals. If that is not possible, at least keep them separate from highest risk groups (kittens, pregnant moms, cats with URI).
- Wear protective clothing when working in a ringworm quarantine room or working with affected animals (long sleeved gown, gloves, shoe covers or boots used only for that purpose). Discard or launder protective clothing daily.
- Disinfect cages and all surfaces in the room twice weekly with diluted bleach (1:32) on a clean surface or Accel® (1:16). Spot cleaning should be performed on a daily basis to minimize disruption and reduce stress and for the cats.
- Dishes and other washable items can be run through a dishwasher provided water temperature reaches at least 110° F (43.3° C).
- Bedding should be washed when soiled or on days when topical treatment is applied. Do not overfill the washing machine as this reduces the machine's ability to mechanically remove ringworm spores. Ringworm laundry should be washed separately from other laundry. Dry ringworm laundry separately and clean lint filters after every use. Bedding or toys that cannot be washed should be discarded.
- Following housing of a ringworm animal, thoroughly clean and disinfect the cage before using the cage for another animal. *For more information, refer to Environmental Decontamination.*
- Carefully clean all areas that cannot be disinfected using a damp mop or electrostatic cleaner such as a Swiffer® followed by vacuuming. Discard the vacuum cleaner bag.

Considerations for Mixing Cats and Kittens

Shelter staff and foster parents are tasked with caring for and adopting out animals who are healthy and well-socialized pets in their future adoptive homes. We want growing animals to be able to experience the world and we want adult animals to be able to express their normal behaviors and have interactions that would enrich their lives. It is important to balance these mental/emotional needs with medical health needs, including preventing the spread of infectious disease. Kittens, in particular, are highly susceptible to infectious disease and special consideration must be given to when it is or is not reasonable to mix them together; in addition, there are some important details to keep in mind when mixing unrelated cats of any age.

Limitations on capacity - staff, time, and/or number of foster homes or amount of cage space - can pose challenges to providing the care necessary to move animals efficiently and safely to the point of adoption. These challenges may lead some shelters to make a choice to mix unrelated cats or kittens together just in order to find more "space". However, that choice often leads to more challenges rather than fewer if the choices of which cats to mix are not balanced against ability to screen for and recognize signs of infectious disease. *For more information, refer to [Considerations for Mixing Cats and Kittens in the Guide to Raising Underage Kittens](#).*

Environmental Decontamination

The foundation of environmental decontamination is identification, removal and treatment (if a shelter has the appropriate housing/space and resources) of affected animals coupled with careful mechanical cleaning. Disinfection is an important part of the protocol but is adjunct to mechanical removal.

Clean all surfaces three times with any good detergent and clean rags. Follow this mechanical removal with a disinfectant. Concentrated bleach or even diluted at 1:10 is too harsh to be routinely used and thankfully is not necessary. Effective disinfectants include Accel/Rescue® (Accelerated hydrogen peroxide 1:16), Accel® TB (hydrogen peroxide 0.5%), Enilconazole, bleach diluted 1:32 with prolonged contact time (at least 10 minutes), 2% Potassium Peroxymonosulfate, Formula 409® (quaternary ammonium 0.3%), and Clorox Clean-Up® (sodium hypochlorite 1.84%,). These have all been shown to be very effective on pre-cleaned surfaces where all organic matter has been removed. For additional specific information regarding the efficacy of various cleaning compounds against ringworm spores, see this [2013 study in Veterinary Dermatology](#).

High heat (> 110°F) is also effective. This temperature can be attained by commercial dishwashers, some commercial steam applicators (but not necessarily home steam carpet cleaners) and clothes dryers.

Environmental Cure: the 5 D's

Environmental decontamination is usually straightforward in a typical shelter with easily disinfected and mechanically cleaned cages. It can present a much greater problem in a home or more home-like environment such as a group cat room.

Application of harsh disinfectants to every contaminated surface is an impossible goal in such environments. Fortunately, much can be accomplished through identification, removal and treatment of carrier animals, followed by repeated application of elbow grease.

Fungal cultures from the environment can take the guesswork out of decontamination, and spare a lot of unnecessary work and worry. First clean carefully and disinfect where possible, then take cultures of possibly contaminated areas to evaluate success (see below for Swiffer swab method.) If the culture is negative, the area can probably be safely re-opened to feline inhabitants. If positive, at least you know for sure you have to go back and try again. This can save a lot of agony over whether to replace carpets, furniture etc. The five D's of ringworm decontamination are:

- Diagnose
 - Recognize and treat infected and carrier animals. No amount of cleaning or disinfection will work if one or more animals are re-contaminating the environment.
 - Remember to check other pets in a foster home, especially cats.
 - Human lesions also need to be identified and treated.
- Discard
 - Heavily exposed items such as scratching posts that cannot be easily washed or disinfected should be discarded.
- Debulk

- Careful mechanical cleaning goes a long way towards removing ringworm contamination.
- This includes clearing cluttered surfaces, use of an electrostatic cleaning product such as a Swiffer® to remove as much dust and hair as possible from every surface, and vacuuming of all accessible areas.
- Commercial steam cleaning of carpets may be helpful for both mechanical cleaning and heat destruction of spores.
- Where possible, furnace filters and air vents should be cleaned and/or replaced. However, cleaning of duct work is often not necessary.
- Disinfect
 - After removal of organic matter (three times with a detergent and clean rag), use an effective disinfectant such as Accel/Rescue® 1:16, Accel® TB (hydrogen peroxide 0.5%), Enilconazole, bleach at 1:32 dilution, 2% Potassium Peroxymonosulfate, Formula 409® (quaternary ammonium 0.3%), or Clorox Clean-Up® (sodium hypochlorite 1.84%).
- Document success through environmental culture
 - Cut Swiffer® into small sections, wipe possibly contaminated surfaces until visibly dirty.
 - Press Swiffer® repeatedly onto fungal culture plate, then culture as usual.

Repeat the five D's as necessary until environmental cultures are negative!

Risk assessment: How do you decide how much to worry about exposed animals?

Risk assessment for exposed animals:

When any animal from a population is diagnosed with ringworm, the following questions arise: what do you do about the other animals in the environment? Do they all need to be cultured? Must they all be isolated while awaiting culture results? Will they all need treatment?

The answers to these questions are dependent on several factors. Not all animals in the same house or even the same room as a ringworm-infected animal will become infected themselves. The risk of infection depends on the animal's individual immune status and grooming habits, the overall cleanliness of the environment, and the level of proximity between the exposed and infected animals. Some questions to ask include: What is the baseline sanitation level? Is this a highly cleanable environment such as a bank of stainless steel cages in an otherwise empty room? Is this a home with lots of scratching posts, furniture and carpeting to collect spores? Somewhere in between, such as a bank of cages in a messy room, with lots of junk piled about? Is bleach or Accel used on a routine basis for disinfection? How closely exposed were the animals? Were they each in separate cages, with minimal handling by staff likely to be carrying infection on their clothing? Was there some shared space such as an exercise area or "get acquainted room" where the animals congregate or spend time without cleaning between occupants? Are cats allowed to wander loose during cleaning but caged separately otherwise?

Is there evidence of spread? Has more than one animals been affected? Are all affected cats from one area of the shelter, or has it shown up in more than one room? Are animals that have been in the shelter long term (> 2-4 weeks) affected? (This suggests acquisition of infection in the shelter, as opposed to coming in already infected).

If the environment is basically clean, animals are generally kept reasonably separated, and overall animal health is good, it is not uncommon for animals to survive a minor exposure without becoming infected. Ideally, all exposed animals will be toothbrush-cultured, but this is often impractical and may not be necessary in a reasonably well-run shelter.

On the other hand, toothbrush cultures all around are generally required in a foster home where there are extensive opportunities for contact, in a cage-free cat shelter or group cat room, or any time there is evidence of significant spread (multiple cats affected). For more information on interpretation of fungal cultures ("pathogen scores") and management based on culture results, please see [Dermatophyte Treatment in a Nutshell](#).

In the event of a true outbreak, many shelters will find it impossible to shut down intake for the duration of treatment. In such cases, it will be necessary to create a clean, separate area for new incoming cats. If this is impossible, a single dip in lime sulfur at intake can reduce the chances of infection if cats must be admitted to a contaminated environment. Please note that this is not recommended as a routine intake procedure for cats and kittens.

As is always the case, prevention of an infectious disease outbreak is far cheaper and easier on all concerned than management of an outbreak. After an outbreak of any kind, all personnel should meet to ensure that all staff and volunteers understand how the situation came about and what methods of control were most effective in ending the outbreak. From this informational meeting, a plan to prevent outbreaks in the future should be developed, written down, posted and distributed, so that all involved are aware of their role in prevention of future outbreaks.

Managing Ringworm in a Foster Home or Private Home

Daily cleaning will minimize the amount of environmental contamination that builds up while affected animals are housed there. In addition, thorough cleaning will be needed after the affected animals have left the environment (or recovered). This will be much easier if animals are limited to a small area of the house that has minimal furniture and carpeting (e.g. a large dog crate, bathroom). This is particularly critical until the first two weeks of effective topical treatment have been completed, and ideally until at least one negative fungal culture has been obtained.

Cleaning the Home Environment in the Event of a Ringworm Infection

Daily:

- All non-porous surfaces should be damp mopped, Swiffered® and/or

- vacuumed (to gather up infectious hairs) and disinfected with bleach or Accel. This includes floors, walls, countertops, windowsills, and carriers.
- Rugs should be vacuumed twice daily. Vacuum cleaner bags should be regularly discarded.
 - Bedding and protective clothing should be changed daily, and laundered separately in hot water with a quarter cup of bleach and dried in a dryer (or discarded).

After affected animals have been cleared out, follow the five Ds as previously described in *Environmental Cure: the 5 D's*. The extent to which extensive cleaning will be necessary depends on the level of environmental contamination. If kittens romped through the house for some time before diagnosis, or an effective topical treatment was not used consistently, extensive efforts may be required. If, on the other hand, the cat was kept reasonably confined to a cleanable area and effectively treated from the outside, basic cleaning may be adequate.

Some Steps to Consider Include:

- All exposed animals should be tested for ringworm as described above to make sure they are not sub-clinically affected.
- All exposed bedding, toys, brushes, etc. should be laundered/dried or discarded.
- All non-porous surfaces should be thoroughly cleaned and disinfected where possible with bleach (1:32 dilution) or Accel/Rescue®. This should be repeated at least twice. If bleach is used, it must be applied to a pre-cleaned surface and be rinsed off after sufficient contact time (at least 10 minutes of wet contact).
- All exposed carpets and furniture should be vacuumed daily for one week, and the vacuum cleaner bags discarded daily.
- All heating and cooling vents should be vacuumed or filters replaced. It is not usually necessary to have ducts commercially cleaned.
- Carpets should be commercially steam cleaned. Steam cleaning with cleaners that use hot tap water is ineffective, as the water does not reach a high enough temperature.
- Clothing that was worn when in contact with the cats should be washed in hot water with bleach, then dried in a dryer or by hanging in sunlight.
- Environmental cultures should be performed to verify success of decontamination prior to re-opening the foster home to new animals.

Summary of Ringworm Prevention and Treatment

- There is no effective vaccine against ringworm.
- There is no absolutely reliable screening test.
- Practice good husbandry - keep animals clean and well-nourished, treat other diseases and against external and internal parasites and always avoid crowding and minimize stress.
- Avoid mixing kittens with adult cats and with unrelated kittens. In the case of single kittens or a surrogate queen, then weigh the pros and the cons.
- Perform careful visual exam of all incoming animals and isolate suspects.
- Further screening of foster and group housing candidates as described previously.

- During an outbreak or in areas that have frequent problems with ringworm, separate housing of all kittens in an easy to disinfect area for at least two weeks, followed by careful re-inspection for signs of ringworm.
- Develop a clear written protocol for handling ringworm, and ensure that staff and foster care providers are familiar with this protocol and the signs of ringworm.

Resources

[Beating Ringworm Webinar Series](#) on ASPCAPro.org

Moriello, Karen A., and Sandra Newbury. "Dermatophytosis." In *Infectious Disease Management in Animal Shelters*, 1st ed., 243-73. Wiley-Blackwell, 2009.